

Case report

Complex regional pain syndrome in a 15-year-old girl successfully treated with continuous epidural anesthesia

Yoshiaki Saito^{a,*}, Shimpei Baba^a, Akio Takahashi^b, Daichi Sone^c, Natsuko Akashi^d,
Reiko Koichihara^a, Akihiko Ishiyama^a, Takashi Saito^a, Hirofumi Komaki^a,
Eiji Nakagawa^a, Kenji Sugai^a, Masayuki Sasaki^a, Taisuke Otsuki^b

^a Department of Child Neurology, National Center of Neurology and Psychiatry (NCNP), Kodaira, Tokyo, Japan

^b Department of Neurosurgery, NCNP, Kodaira, Tokyo, Japan

^c Department of Psychiatry, NCNP, Kodaira, Tokyo, Japan

^d Department of Pain Clinic, NTT Medical Center Tokyo, Shinagawa, Tokyo, Japan

Received 17 February 2014; received in revised form 18 March 2014; accepted 18 March 2014

Abstract

A 15-year-old girl developed severe pain in her right upper limb within a few days after she experienced an astatic epileptic seizure accompanied by falling on her right side. She was treated with fluid infusion through a cannula into her right hand. Swelling, mild flaring, and muscle weakness of the right arm subsequently appeared. Pharmacotherapy and stellate ganglion block were ineffective, and continuous epidural anesthesia was commenced 14 days after the falling event. The pain and accompanying symptoms completely disappeared within 5 days. Early treatment with continuous epidural anesthesia may be a promising option for the management of complex regional pain syndrome during childhood.

© 2014 The Japanese Society of Child Neurology. Published by Elsevier B.V. All rights reserved.

Keywords: Complex regional pain syndrome (CRPS); Reflex sympathetic dystrophy (RSD); Nerve block; Continuous epidural anesthesia

1. Introduction

Complex regional pain syndrome (CRPS) type I is a condition that is often triggered by trauma or blood puncture of the extremities, and it is characterized by devastating pain disproportionate in severity and persistence to the precipitating event, and various autonomic manifestations, including vasomotor instability and residual motor disabilities [1]. Onset of less than 10%

CRPS cases happens during childhood and adolescence [2], and occurs predominantly in young adolescent girls. Although early initiation of treatment correlates with a better prognosis in CRPS [3], the relatively rare association of childhood CRPS with preceding traumatic events compared with adult CRPS and the under-recognition of this syndrome by pediatricians often result in considerable delay in proper diagnosis.

CRPS was formerly called reflex sympathetic dystrophy, but this term was discarded because the assumption of sympathetic nerve hyperactivity was not validated. The pathophysiology of the syndrome remains unclear, with no definitive hallmark for the prediction of outcome, and the effect of each treatment regimen varies considerably among individual patients. These factors

* Corresponding author. Address: Department of Child Neurology, National Center of Neurology and Psychiatry, 4-1-1 Ogawahigashi-cho, Kodaira, Tokyo 187-8551, Japan. Tel.: +81 42 341 2711; fax: +81 42 346 1705.

E-mail address: saitoyo@ncnp.go.jp (Y. Saito).

have led to certain controversies regarding treatment strategy. The classic literature suggests that childhood CRPS is generally self-limited and has a better prognosis than adult CRPS, and that conservative management by physiotherapy with a mobilization program is sufficient [4]. Furthermore, some authors claim that psychological problems play a significant role in the pathogenesis of childhood CRPS, and that medication and nerve stimulation/block therapies are inappropriate because these allow family members to avoid facing the psychosocial issues [5]. However, the efficacy of physiotherapy for CRPS was not proved by a randomized control trial [6]. Residual pain in young adulthood has been recognized in at least half of sufferers [7]. There are children with refractory courses and/or persistent trophic sequelae [8] and invasive treatment, including sympathetic blocks, may need to be considered in some cases. Here, we report the case of a girl who showed early and complete recovery from CRPS, achieved by continuous epidural anesthesia.

2. Case report

The patient was a 15-year-old, right-handed girl who developed normally until the age of 9 years, when she developed weekly epileptic seizures with visual and/or olfactory aura accompanying impairment of consciousness. Brief seizures persisted after treatment with clobazam, occurring once or twice per year, and she was referred to our hospital for further evaluation. The neurological findings were unremarkable, and her intelligence quotient was assessed as 117 on the Wechsler Intelligence Scale for Children-IV, with scores in subscales of Verbal Comprehension Index 105, Perceptual Reasoning Index 113, Working Memory Index 120, and Processing Speed Index 113. Interictal electroencephalography (EEG) showed frequent spikes over the right frontotemporal area. Magnetic resonance imaging revealed a gadolinium-enhanced lesion at the right temporal tip (Fig. 1A and B). Thereafter, she experienced weekly episodes of nausea with trembling of the body and hand, visual hallucination of herself and family members, sensation of ear fullness, or brief visual disturbance. A 96-h video monitoring EEG under reduction of clobazam dosage identified four episodes of motion arrest with impaired consciousness coincident with the emergence rhythmic theta waves over the right frontotemporal region. Moreover, trembling of the body appeared several times, which was not accompanied by a change in EEG. As we had evidence of true epileptic seizures, lesionectomy was planned.

Two months later, the patient experienced a seizure with headache, nausea, and unconsciousness at school. She fell down and hit her right shoulder on the floor. She was referred to a local hospital, and was subjected to blood examinations and treatment with fluid infusion

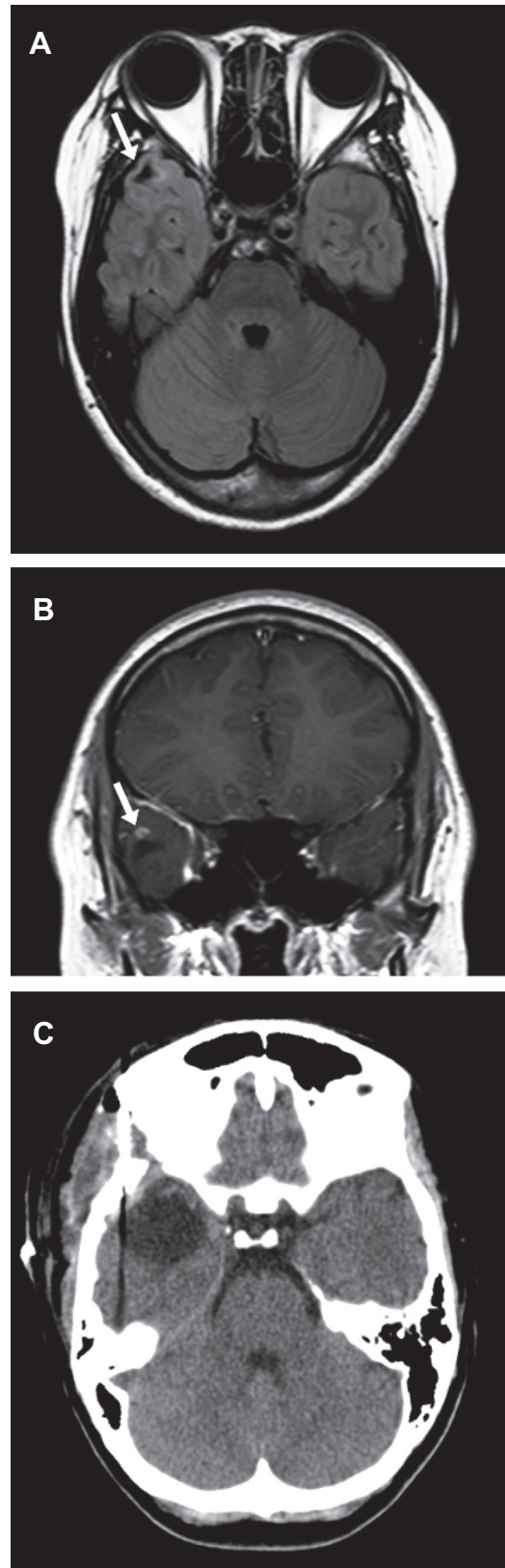


Fig. 1. Neuroimaging of the patient. (A) Fluid-attenuated inversion recovery image. (B) Gadolinium-enhanced image. (C) Computed tomography of the brain after lesionectomy. In A, a lesion with low signal intensity (arrow), partly rimmed by high signal striae, is visible. In B, a peripheral area of the lesion is enhanced (arrow).

into the dorsum of her right hand. On returning home after recovery, she experienced dysesthesia on the dorsum of her right hand in the evening. Pain in the hand intensified gradually, and radiated to the right shoulder by the next morning. Burning pain with allodynia of the complete right upper limb persisted, accompanied by swelling and a reddish color change of the hand and forearm (Fig. 2A and B). The patient could not move her fingers and wrist/elbow joints because of intense pain on day 3 of her illness. Radiographs of the right upper limb were normal. The right upper limb turned a pale color. CRPS was suspected and neurotrophin, amitriptyline, loxoprofen, tramadol, and pregabalin were prescribed, but no effect was observed. The patient was admitted to the pain clinic on day 12 of her illness. The results obtained from blood examination, including cell counts, coagulation status, and C-reactive protein, were normal. Although stellate ganglion block was performed twice, she experienced pain relief only for a few hours. Continuous epidural anesthesia with ropivacaine (2.5 mg/h) through an epidural cannula placed at Th1 level (Fig. 2C) was commenced on day 14, resulting in complete resolution of pain. She remained pain-free after anesthesia was terminated on day 19, and underwent a rehabilitation program until complete recovery of motor function, which occurred within a week. Scales appeared on her fingers during these periods (Fig. 2D).

The frontotemporal lesion was successfully resected 8 months later (Fig. 1C) without postoperative recurrence of CRPS symptoms, resulting in disappearance of habitual seizures. A psychological interview during the preoperative period disclosed that the family had marital discord and the patient had experienced visual

hallucinations since the age of 5 years. The patient believed that successful surgical treatment leading to the termination of antiepileptic treatment would help restore the family environment.

3. Discussion

The literature has several cases of CRPS complicating brain tumor, but there is no evidence that the tumor itself had a definite role in the pathogenesis of CRPS in the present patient. In contrast to the characteristics of childhood CRPS, including the lower limb involvement and the lack of preceding traumatic events [4], the manifestations of the present patient were rather typical of adult CRPS. This prompted early diagnosis and intervention. Because medication and stellate ganglion blockade during the first 2 weeks of treatment had little effect, we decided to institute continuous epidural anesthesia, which is reported to be effective in adult CRPS [9].

Physiotherapy with mobilization is recommended as the first-line treatment for CRPS, but burning pain rendered the present patient entirely unable to move her affected limb, and pain relief by analgesia allowed pain-free mobilization. Of 37 adult CRPS patients treated with continuous epidural infusion of bupivacaine and fentanyl [9], approximately 90% improved significantly when treated within 1 year after onset of symptoms, whereas the success rate decreased dramatically when treatment was initiated more than 1 year after onset and when more than one limb was involved [9]. As mentioned above, children with CRPS have been reported to have a better prognosis than adults, and are treated conservatively with physiotherapy and oral analgesics rather than invasive intervention. In previous reports, physiotherapy with mobilization program had been initiated within one week after the onset of CRPS and successfully conducted in children who achieved complete recovery within 2–3 weeks [10]. A tentative, six-week waiting period of conservative treatment before initiation of continuous epidural block was recommended for adult CRPS [11]. Having our additional experience that early administration of continuous epidural anesthesia resulted in rapid recovery of the present patient, we consider that anesthesia coupled with physiotherapy, particularly within several weeks after onset, would be a promising option for severe childhood CRPS refractory to the initial treatment.

We were concerned that the insult of epileptic surgery may precipitate the recurrence of CRPS in our patient. On the other hand, the recurrence rate of CRPS was calculated to be only 1.8% per patient per year in a large case series, and the interval between the first and second CRPS episodes varied from 3 months to 20 years [12]. The latter finding may imply that surgery after waiting several years does not guarantee a lower risk

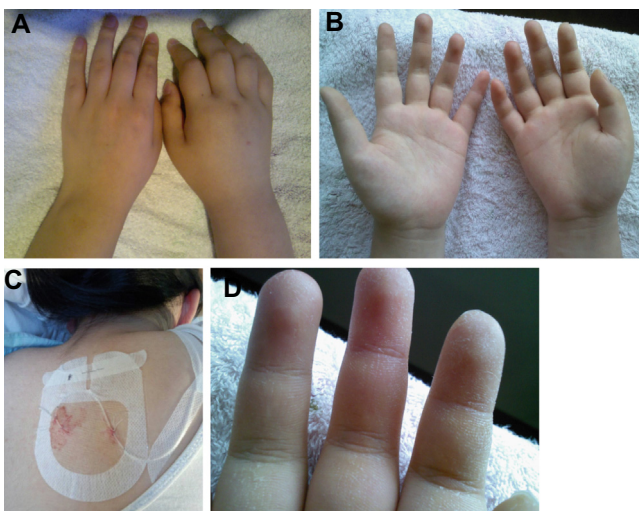


Fig. 2. Photographs of the patient. (A and B) On day 8 of her illness, the fingers of her right hand were swollen. (C) The tip of epidural cannula placed at Th1 level for continuous epidural anesthesia. (D) During recovery, fine scales were observed on the affected fingers on day 14 of illness.

of recurrence. This information was discussed with the family of our patient before deciding to perform the surgery.

Although their exact role in the pathophysiology of this CRPS remains unclear, psychosomatic reactions to psychological stress, a high level of responsibility for the subject's age, and an unstable home environment have been regarded as common psychosocial traits in children with CRPS [5]. Furthermore, the development of somatization disorder, dissociative episodes, and post-traumatic stress disorders are also common in CRPS sufferers [13]. The psychosocial characteristics of the present patient certainly underscore these factors as determinants of susceptibility to CRPS. Of importance in clinical practice, dissociative visual hallucinations and psychosomatic symptoms needed to be distinguished from true epileptic seizures in our patient. Video-monitored EEG and psychological interview facilitated correct evaluation of the patient's condition. Possible favorable effects of psychological interview and support for improving the family environment on the amelioration of CRPS symptoms and prevention of recurrence remain to be explored.

In conclusion, the present case provides a basis for an invasive intervention for pain relief in childhood CRPS. Early treatment with continuous epidural anesthesia may be promising when initial treatment with mobilization program, medication, and stellate ganglion blockade are ineffective. Carefully interviewing the patient for co-existing psychological problems should lead to better management of childhood CRPS.

Acknowledgements

This study was supported in part by Intramural Research Grant (24-8, 25-3, 25-6; Clinical Research for Diagnostic and Therapeutic Innovations in Develop-

mental Disorders) for Neurological and Psychiatric Disorders of NCNP.

References

- [1] Veldman PH, Reynen HM, Arntz IE, Goris RJ. Signs and symptoms of reflex sympathetic dystrophy: prospective study of 829 patients. *Lancet* 1993;342:1012–6.
- [2] Tan EC, Zijlstra B, Essink ML, Goris RJ, Severijnen RS. Complex regional pain syndrome type I in children. *Acta Paediatr* 2008;97:875–9.
- [3] Dietz FR, Mathews KD, Montgomery WJ. Reflex sympathetic dystrophy in children. *Clin Orthop Relat Res* 1990;258:225–31.
- [4] Bernstein BH, Singsen BH, Kent JT, Kornreich H, King K, Hicks R, et al. Reflex neurovascular dystrophy in childhood. *J Pediatr* 1978;93:211–5.
- [5] Sherry DD, Weisman R. Psychologic aspects of childhood reflex neurovascular dystrophy. *Pediatrics* 1988;81:572–8.
- [6] Oerlemans HM, Oostendorp RA, de Boo T, Goris RJ. Pain and reduced mobility in complex regional pain syndrome I: outcome of a prospective randomised controlled clinical trial of adjuvant physical therapy versus occupational therapy. *Pain* 1999;83:77–83.
- [7] Tan EC, van de Sandt-Renkema N, Krabbe PF, Aronson DC, Severijnen RS. Quality of life in adults with childhood-onset of Complex Regional Pain Syndrome type I. *Injury* 2009;40:901–4.
- [8] Rush PJ, Wilmot D, Saunders N, Gladman D, Shore A. Severe reflex neurovascular dystrophy in childhood. *Arthritis Rheum* 1985;28:952–6.
- [9] Moufawad S, Malak O, Mekhail NA. Epidural infusion of opiates and local anesthetics for Complex Regional Pain Syndrome. *Pain Pract* 2002;2:81–6.
- [10] Aftimos S. Reflex neurovascular dystrophy in children. *N Z Med J* 1986;99:761–3.
- [11] Cooper DE, DeLee JC, Ramamurthy S. Reflex sympathetic dystrophy of the knee. Treatment using continuous epidural anesthesia. *J Bone Joint Surg Am* 1989;71:365–9.
- [12] Veldman PH, Goris RJ. Multiple reflex sympathetic dystrophy. Which patients are at risk for developing a recurrence of reflex sympathetic dystrophy in the same or another limb. *Pain* 1996;64:463–6.
- [13] Grande LA, Loeser JD, Ozuma J, Ashleigh A, Samii A. Complex regional pain syndrome as a stress response. *Pain* 2004;110:495–8.