

Erratum

The publishers and the authors would like to make the following correction:

BRADEV 000144

A case of chronic epileptic encephalopathy of neonatal onset: a probable concern of human cytomegalovirus

Kohyama, J., Suzuki, N., Kajiwara, M., Shimohira, M., Iwakawa, Y.

(BRADEV 00093: *Brain Dev* 1993; 15: 448-52)

Fig. 1 in this article was published with the vertical calibration bar missing. The correct figure with its legend is reproduced below.

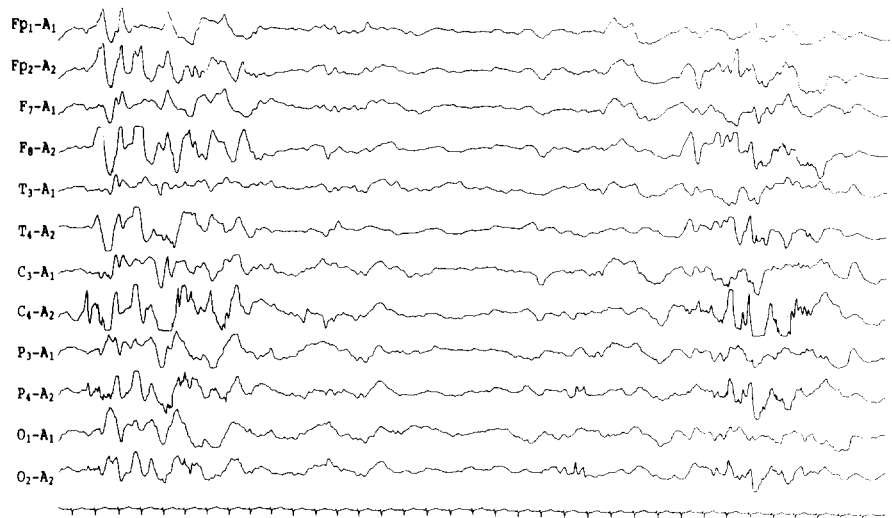


Fig. 1. A part of the drug-induced sleep EEG of the patient at first admission (25th day of life). High voltage paroxysmal discharges, predominantly on the right side, with insertion of suppressed activity (suppression-burst pattern) can be seen. Calibration: 1 s and 100 μ V.

The publishers apologise for any inconvenience this error may have caused.